

The New England Journal of Medicine

Copyright, 1946, by the Massachusetts Medical Society

Volume 234

JUNE 20, 1946

Number 25

GASTRIC SURGERY*

FRANK H. LAHEY, M.D.†

BOSTON,

SINCE this paper is presented before and will be read largely by physicians interested in the general practice of medicine, in it I will try to cover briefly many of the conditions in which surgery is applicable in the stomach, duodenum and jejunum, and our experiences with them. The latter two structures will be included because their surgical management, either by subtotal gastrectomy or by gastroenterostomy, involves the stomach at the time of the primary surgical procedure and even more seriously involves it when secondary complications, such as gastrojejunal ulcer and gastrojejunal fistulas, occur.

HIATUS HERNIA

If we consider gastric lesions in relation to their anatomic level, and start with the cardia, we can first consider the question of hiatus hernia and, together with hiatus hernia, peptic ulcer of the lower end of the esophagus, which occasionally develops as a result of the hernia.

Hiatus hernia is by no means an uncommon lesion. It is characterized by digestive disturbances and by pain beneath the sternum easily confused with anginal pain. It varies in intensity from acute episodes when good-sized sections of the upper stomach are trapped and distended in the hiatus hernia to the very vague digestive symptoms and very moderate degrees of distress that are associated with small openings through which but small sections of the stomach protrude into the pleural cavity (Figs. 1 and 2).

The management of most of these lesions has been successfully accomplished by the Gastroenterological Department of the clinic by medical measures.

Since most of the symptoms associated with hiatus hernia are the result of distention of the herniated portion of the stomach, nonoperative measures are directed largely toward the attainment of more normal digestive function and the avoidance of gastric distention. With the establishment of a careful dietary regimen and the avoidance of laxa-

tives, there have been few of these patients who have but moderate-sized hernias in whom it has not been possible, without surgical interference, to maintain reasonable digestive comfort and to overcome the substernal pain of which most of these patients complain.

We have in the past in a number of these cases attempted to obtain relief by phrenicotomy, but with increased experience in their nonoperative

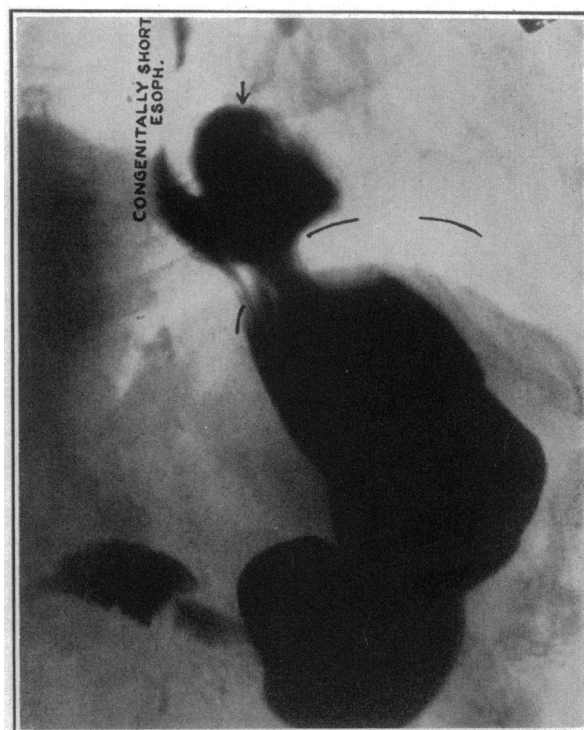


FIGURE 1. Roentgenogram of a Small Hiatus Hernia Associated with a Congenitally Short Esophagus.

management, this procedure has been rarely necessary, and in the cases in which it has been done it has not added significantly to the benefits that can be obtained by medical management alone.

In hiatus hernias with large defects in which good-sized portions of the stomach pass through the

*The Annual Oration, delivered at the annual meeting of the Massachusetts Medical Society, Boston, May 22, 1946.

From the Department of Surgery, Lahey Clinic.

†Director, Lahey Clinic.

diaphragm, repair of this defect has occasionally been necessary. It presents no technical problems of great difficulty except to be certain that the aperture is adequately closed without producing obstruction.

PEPTIC ULCER OF THE ESOPHAGUS

Dr. Donald T. Chamberlain¹ has reported from this clinic the occurrence of 7 peptic ulcers of the lower end of the esophagus. One of these was due to the occurrence of a peptic ulcer in aberrant gastric mucosa; the remainder were associated with and probably brought on by hiatus hernia.

These lesions are probably brought about by the congestion in the mucosa as the upper end of the stomach and lower end of the esophagus rub against the edge of the aperture in the diaphragm, together

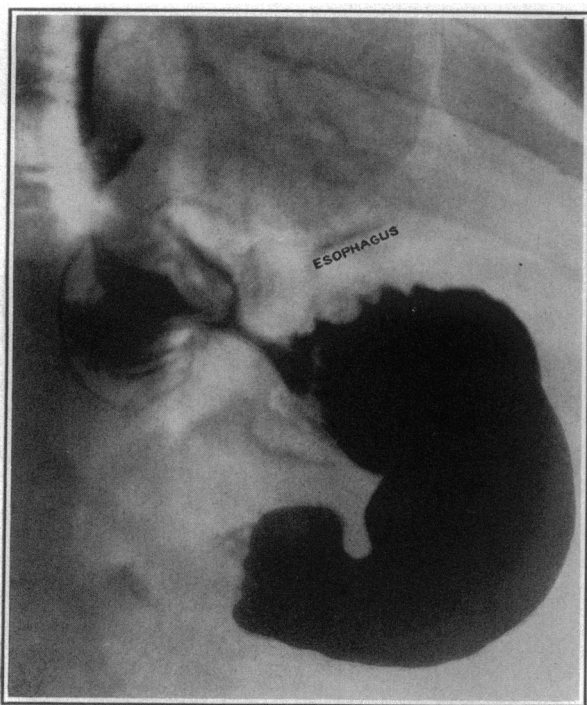

FIGURE 2. Roentgenogram of a Sizable Hiatus Hernia above the Level of the Diaphragm.

It is quite well distended and in the state of distention that produces symptoms.

with the fact that in the trapped segment of stomach there occurs a high gastric acidity, thus providing favorable conditions — congestion associated with gastric contents having high acid values — for the production of a peptic ulcer. These are the conditions that, when brought about in experimental animals, make it possible to produce experimental peptic ulcer (Fig. 3).

In patients presenting typical ulcer symptoms with high acidity, hunger pain and food relief, and in the absence of any visible defect in the stomach

or duodenum as shown by the roentgenogram, one must have in mind the possible presence of such a peptic ulcer in the esophagus.

Dr. Everett D. Kiefer, of the Gastroenterological Department of the clinic, has set up the criteria for the diagnosis of these lesions: there must be a high

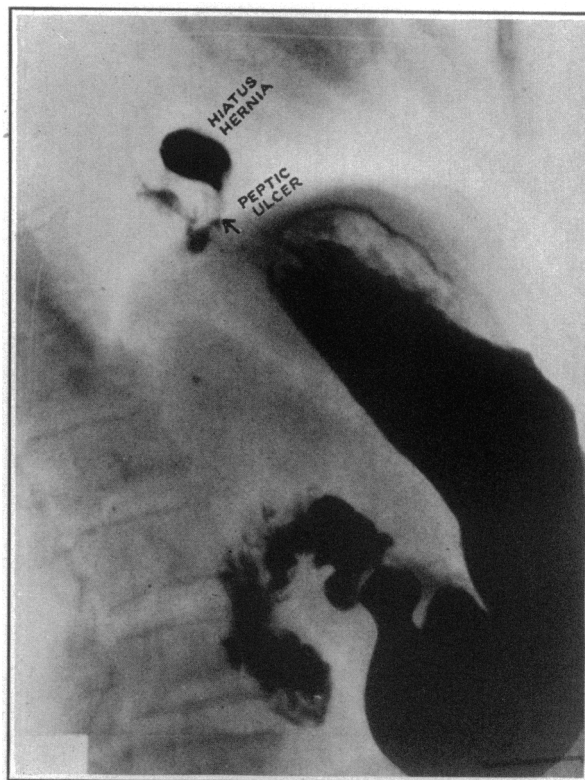


FIGURE 3. Roentgenogram of a Small Hiatus Hernia Associated with a Peptic Ulcer.

The ulcer is shown by the fleck at the point of the arrow. Note the relation of this ulcer to the diaphragm, which can be seen as a shadow. This patient was relieved of all symptoms by ulcer treatment.

gastric acid value; typical ulcer symptoms must be relieved by food and alkali; the ulcer must be visualized by esophagoscopy; and the symptoms must disappear after nonoperative ulcer management. All these patients have been successfully managed without operation, and the subject is discussed merely as a reminder of the occurrence of this lesion in a patient with ulcer symptoms but with no ulcer demonstrable in the usual locations.

CARCINOMA OF THE CARDIA AND LOWER ESOPHAGUS

One of the lesions that has now become surgically approachable is carcinoma of the cardiac end of the stomach, so often spreading over onto the lower end of the esophagus, or vice versa.

The surgical management of these lesions by means of the transthoracic approach has been so

well established that everyone should be on the lookout to diagnose carcinomas of the upper end of the stomach or lower end of the esophagus earlier than they have been diagnosed in the past. Carcinomas of the lower end of the esophagus and upper end of the stomach, on the basis of autopsy figures from large hospitals, represent 5 per cent of

surgery, have operated on most of these patients, the mortality has progressively diminished until it is now within very reasonable figures.

GASTRIC ULCER

The problem of gastric ulcer is one that has occupied the attention of gastroenterologists and surgeons over a great many years, largely owing to the relation between gastric ulcer and gastric cancer.

Over the past years we have taken the position that a great many gastric ulcers can be healed and will remain healed under medical management. We have demonstrated this to our satisfaction, and if one could be certain concerning his ability to determine safely which lesion is benign and which lesion is malignant, I should personally be willing to continue with this program. But now, at the end of several years' experience with this position, I believe that it should be changed to the position

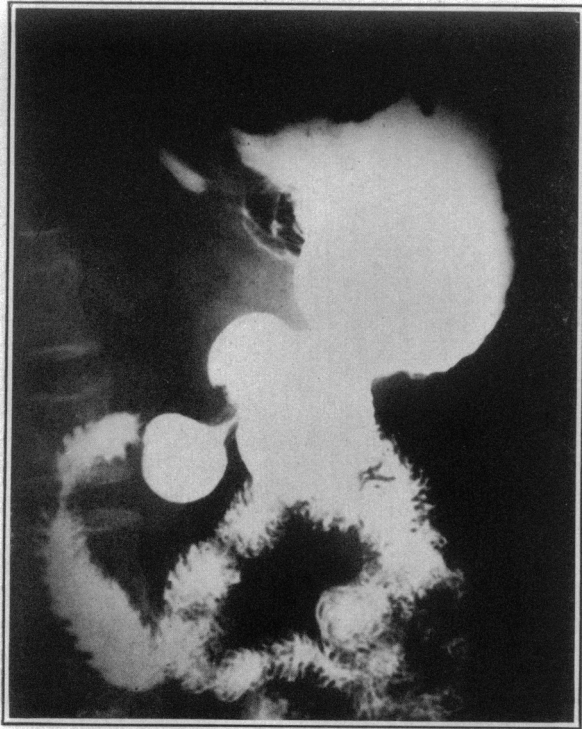

FIGURE 4. *Preoperative Roentgenogram of a Carcinoma of the Lower End of the Esophagus.*

This was resected transthoracically through the diaphragm, the stomach being pulled up into the chest and anastomosed to the esophagus to make up for the defect.

all carcinomas found at autopsy. Over the years our attitude toward malignant lesions in this location has been so pessimistic that we have not concentrated sufficiently on their early diagnosis. With these lesions now so removable by means of radical surgery, the slightest feeling of discomfort in the lower esophagus, the most trivial degrees of obstruction and the most vague digestive symptoms must be thoroughly investigated with regard to the possibility of this lesion if we are to make full use of the surgical facilities now at hand in attempting to cure a greater number of these patients (Figs. 4, 5 and 6).

Mortality figures in these patients submitted to resections of the lower end of the esophagus and upper end of the stomach are shown in Table 1. It is to be noted that, with increasing experience in the hands of Dr. Ralph Adams and Dr. Herbert D. Adams, who, because of their interest in chest

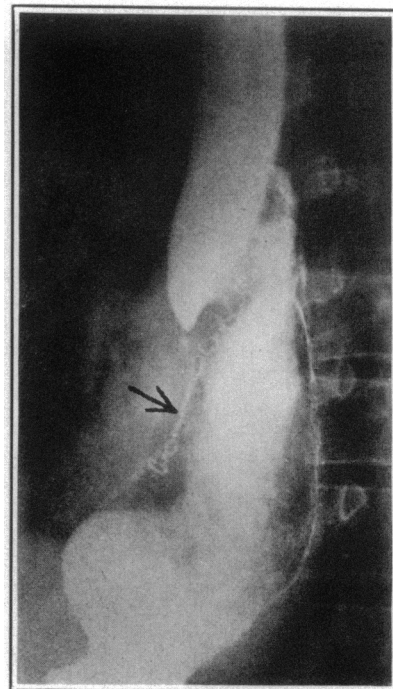


FIGURE 5. *Postoperative Roentgenogram after Transthoracic and Transdiaphragmatic Resection.*

Note the clips of the von Peitz sewing machine where the stomach has been transected and the end turned in. The anastomosis of the now intrathoracic stomach to the lower end of the esophagus and the dilatation of the esophagus during peristalsis are shown.

that all gastric ulcers, provided the patient is a reasonably good risk, should be submitted to operation. This seems a radical position to take, particularly in the light of some of our previous statements, and some of our previous experiences with these lesions, which have healed under nonoperative management, but I have personally come to this conclusion for the following reason. The results in the surgical treatment of gastric cancers are so de-

pressing that there must be some radical change in our attempts to deal with them earlier if we hope to improve these results. It has now been demonstrated beyond reasonable doubt that even in the presence of gastric cancer, apparent healing of the ulcerating lesion can be brought about under good medical management. We have, in addition, in suspicious lesions found it difficult, and at times almost impossible, to make patients return a sufficient number of times for adequate check-up examinations to be certain that what appeared to be a benign lesion was not developing into a malignant

advising subtotal gastrectomy in all cases of gastric ulcer. In a large experience with these lesions, some mistakes have been made in diagnosing ulcer when carcinoma was present, and this, together with a recognition of the fact that nothing but a more aggressive approach to gastric lesions in the way of early radical surgery will improve a field that is now far from satisfactory, brings me to this position.

As already stated, gastric carcinoma is almost the most depressing situation in the entire field of readily approachable surgical lesions. This is

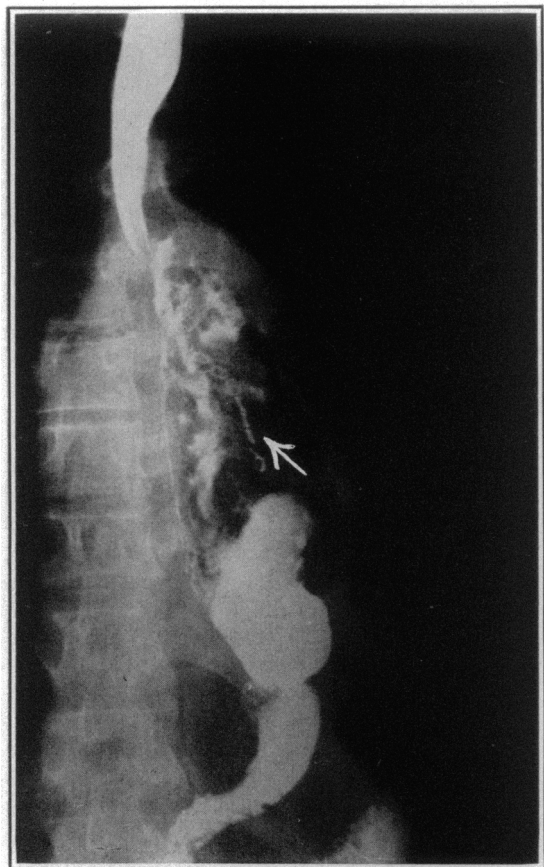


FIGURE 6. Postoperative Roentgenogram after Transthoracic Resection.

This illustration demonstrates how the duodenum has swung to the midline as the result of the altered position of the stomach and gradual traction on the duodenum.

Note again at the arrow the clips of the von Petz sewing machine, showing the transection of the stomach at its midportion.

one. We have now done high subtotal gastrectomies on 85 consecutive patients with gastric ulcer with no mortality. In view of the above consideration, we believe that if this be balanced against the constant danger of wrongly diagnosing a gastric ulcer for early gastric cancer, better results will be obtained and greater progress will be made in the management of gastric cancer by the position of

TABLE 1. Data on Resection of Cardia and Lower Esophagus.

SERIES OF PATIENTS	NO. OF EXPLORATIONS	NO. OF RESECTIONS	NO. OF HOSPITAL SURVIVALS
First (7/1/37 through 12/31/43) . . .	28	16	9
Second (1/1/44 through 4/26/46) . . .	29	14	13
Totals	57	30	22

primarily due to the fact that it is so rarely diagnosed early, which, in turn, is due to certain factors related to this lesion. It produces a low gastric acidity or an acidity and so does not produce the digestive symptoms related to high acidity, as occurs with ulcer; it is an infiltrating lesion and so does not produce early hematemesis; the stomach is of such size that the growth of the lesion produces obstructive symptoms only in the late stages of the disease. As a result of all these factors, the lesion may be fairly well advanced before it produces symptoms of an urgent and distinctive character.

In addition to the above factors, the high vascularity of the stomach, the rich field of lymphatics that surround it and the fact that it is a structure in which active and vigorous motion exists with great frequency produce conditions for early extension outside of the structure itself and result in recurrence today, in spite of radical operation, in over 90 per cent of cases.

To improve the results in carcinoma of the stomach will be difficult. It will involve requirements and conditions that are almost impossible to attain, that is, more complete and involved investigations for relatively minor symptoms, such as earlier gastric analyses, gastroscopies, fluoroscopies and roentgenograms, more frequent explorations of doubtful lesions and the more universal establishment of the position that I am now willing to take, namely, that all patients with gastric ulcer should be submitted to radical surgery.

The mortality figures for the last consecutive series of cases of peptic ulcer are submitted in Table 2, involving cases operated on in the last ten years.

GASTRIC CARCINOMA

Two types of operation are available for the management of gastric cancer—high subtotal gastrectomy and total gastrectomy combined with

splenectomy in order to make the total gastrectomy more radical and the anastomosis of the jejunum to the esophagus easier and safer under good direct vision, as can be done with the spleen removed.

Because palliative operations, such as palliative gastroenterostomy, are so unsatisfactory, are done so often in advanced lesions, provide relief for such a relatively short period of time and have such a high

involved nodes in the omentum, so frequently present in cases of carcinoma of the stomach, but also exposes the posterior wall of the stomach, the gastric artery at its root and the posterior wall of the duodenum so satisfactorily and adequately that it not only increases the radicalness of the procedure but makes it technically much easier to do.

TABLE 2. *Mortality for Cases of Peptic Ulcer (October 1, 1936, to April 1, 1946).*

DIAGNOSIS	NO. OF CASES	NO. OF DEATHS	MORTALITY %
Duodenal ulcer	358	10	2.8
Gastric ulcer	85	0	0.0
Jejunal ulcer	87	2	2.3

mortality rate, we have been less and less interested in doing them. This has resulted in employing subtotal gastrectomy in many of the advanced cases of carcinoma of the stomach in which in the years gone by a palliative procedure, such as gastroenterostomy, would have been performed. This has been done on the basis that an operation in which the lesion itself is removed even when a cure cannot be anticipated is superior to a palliative gastroenterostomy in which the lesion is left behind, soon to invade the new stoma.

This approach results, as might be expected, in a relatively high mortality, 12 per cent in 256 consecutive cases, as may be seen from the statistics (Table 3). It is, however, superior to the palliative operation, in which the mortality is almost twice this figure, 21 per cent.

There are a few things that we have learned in our experience with subtotal gastrectomy for malignant tumors. One is that the operation can be made

TABLE 3. *Mortality for Cases of Carcinoma of the Stomach (October 1, 1936, to April 1, 1946).*

OPERATION	NO. OF CASES	NO. OF DEATHS	MORTALITY %
Subtotal gastrectomy	256	31	12.6
Exploration and biopsy	294	18	6.1
Palliative operation	66	14	21.1

more radical by combining omentumectomy with the subtotal gastrectomy, and the other is that to give these patients with malignancy a real chance, resection must be so high that it cannot be done with stomach clamps. For that reason, all subtotal gastrectomies performed at the clinic during the last eighteen years have been done with the von Petz sewing machine, making it possible to remove four fifths of the stomach in these cases, together with almost the entire omentum.

Omentumectomy, partial or complete, as shown in Figure 7, not only removes metastatically in-

LEIOMYOMA OF STOMACH

In Figure 8 is shown the roentgenogram of a patient with leiomyoma of the stomach, and in Figure 9 is shown the specimen of such a case, removed by subtotal gastrectomy.

I wish particularly to call attention to this lesion, of which we have now had 14 cases. I am especially anxious to call attention to this group of cases because almost all these patients have a history of repeated hemorrhages. In the removed specimen (Fig. 9) will be seen the healed scars representing ulceration of the mucosa over this tumor.

Because of the fact that leiomyomas usually do not produce symptoms except for the frequently profuse hemorrhages that go with them, this bleeding is often suspected of being caused by ulcer and, unless adequate investigation is carried out, many of these patients are treated for ulcer because of the profuseness of the hemorrhage.

It is important that these cases be diagnosed early because of the fact, as I³ have stated in a previous article on this subject, that 71 per cent of these tumors, on removal, have shown sarcomatous degeneration. It is for this reason that I particularly wish to call attention to them and their need for early and radical removal.

There has been no mortality in this group of cases.

TOTAL GASTRECTOMY

Our oldest living patient on whom total gastrectomy was done was operated on October 8, 1937, for a large leiomyosarcoma involving all the stomach. She is, therefore, now alive and well eight years and seven months after operation. This operation, of which we have now done eighty-nine, is really a development of the last ten years. We have applied total gastrectomy in the cases of leiomyosarcoma in which it has the most favorable prospect of cure in that these lesions may involve the entire stomach but still remain of a relatively low grade of malignancy.

We have applied this operation also to the lymphosarcomas because of the fact that, with partial gastrectomy, it is difficult in many of these cases to determine the limit of infiltration because these lesions do not produce a true tumor, but are infiltrating in character. The oldest patient of this group is alive and well seven years and one month after total gastrectomy.

We have also applied this operation to the infiltrating type of carcinoma of the stomach to which

the term "linitis plastica" has been given, owing to the fact that this type of cancer of the stomach, in contradistinction to the localized type, tends to spend its energy more largely in intramural infiltration than in local extension and metastases to the lymph nodes. The oldest patient of this group is now alive and well without recurrence five years and four months after operation.

As already stated, it is in the first group, the multiple leiomyosarcomas involving the entire stomach, that there is the greatest prospect of cure by total

Our position regarding the use of total gastrectomy, therefore, can be stated in the light of our experiences to date with 89 cases in which this operation has been done. Even in cases with complete involvement of the stomach by carcinoma of the linitis plastica type, life can be and has been prolonged from a few months to five years and four months. In the linitis plastica type of carcinoma of the stomach cures cannot be expected, but prolongation of life with comfortable living can be anticipated in many of the cases, if properly selected. In lei-

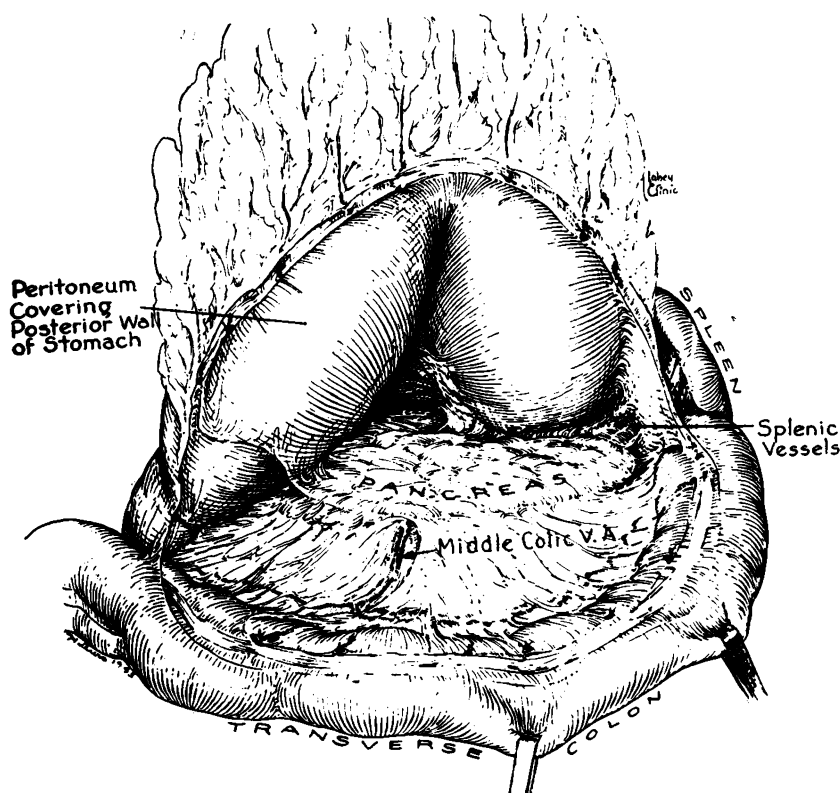


FIGURE 7.

This illustration shows how the omentum can be separated from the transverse colon for omentectomy, together with subtotal or total gastrectomy, and also demonstrates exposure of the posterior wall, the gastric artery and the posterior wall of the duodenum (reproduced from Marshall² by permission of the publisher).

gastrectomy, and it is unlikely in the patients with carcinoma that there will be cases in which the lesions are so extensive that total gastrectomy is indicated in which permanent cures can be expected.

Although it is true that in the linitis plastica type of carcinoma of the stomach, obvious metastases to lymph nodes are often not apparent, it is in all probability equally true, in the cases in which the entire stomach is so involved that total gastrectomy is indicated, that there will be no cases in which some distant metastases have not already taken place and ultimate recurrence is inevitable.

myosarcomas there is a reasonable prospect of cure even when the lesions are extensive and total gastrectomies must be employed. Between the optimistic prospect concerning cure that one may have with patients who have leiomyosarcomas and the pessimistic ultimate prognosis in those in whom the linitis plastica type of carcinoma exists, rests lymphosarcoma of the stomach so far as the prospects of a satisfactory future life are concerned. This experience with total gastrectomy, as shown in our mortality figures, has permitted us to draw certain conclusions: that the operation has now be-

come sufficiently standardized in our hands and in the hands of many other surgeons so that it can be done with a reasonable mortality rate in spite of its magnitude; that patients can survive and live happily and maintain their weight and strength with no stomach and with the proximal loop of jejunum anastomosed to the esophagus, serving as a substitute for a stomach; and that it is necessary postoperatively throughout the remainder of their lives to keep close track of the blood picture in these patients, because of the tendency for anemias to occur. In almost all these cases it has been necessary for the patients to take liver, iron and vitamins. After operation, frequent meals must be

are as follows: 59.7 per cent have a chance of living for 12 months; 38.6 per cent for 18 months; 29.8 per cent for 24 months; and 21.1 per cent for 36 months or more.

DUODENAL ULCER

Duodenal ulcer is the most complicated lesion in my opinion in the entire field of gastric surgery. In this clinic over the past years we have had passed through the Gastroenterological Department for management 8000 patients with duodenal ulcer, of whom approximately 6 per cent have come to surgery. The mortality rate was 1.5 per cent, but as a result of the occurrence of 4 fatalities in the last year is now 2.8 per cent for the past ten years.

This lesion, exclusive of gastrojejunal fistula, has associated with it the highest mortality rate in the entire surgical management of peptic ulcer. It will be noted in the statistical chart (Table 2) that in a consecutive series of 85 cases of resection for gastric ulcer there was no mortality, and that the mortality in 87 consecutive cases of resection for jejunal ulcer, which involves not only subtotal gastrectomy but also resection of the jejunum, was 2.3 per cent, even lower than that for subtotal gastrectomy for duodenal ulcer.

In discussing this lesion and its surgical management, I have again and again stated that the mortality of duodenal ulcer is not the result of the subtotal gastrectomy but of the relation of the duodenal ulcer to the head of the pancreas, into which it so frequently erodes, and to the common bile duct, to which it is so often intimately attached by the induration and scarring associated with it.

We have taken the position over the years that, when possible with reasonable safety, we should always remove the duodenal ulcer and that part of the duodenum in which it occurs. We do not believe that the removal of the duodenal ulcer is essential to bring about a cure with subtotal gastrectomy, but that its removal is often essential if one wishes to obtain enough flexible duodenal stump so that it can be safely inverted without the danger of a duodenal fistula. It has been our desire to avoid the occurrence of a duodenal fistula, representing as it does leakage, the danger of digestion of the fistula wall and the always possible occurrence of a fatality. It is for this reason, not the mere removal of the ulcer, that we have advocated that, included in the subtotal gastrectomy for duodenal ulcer, whenever reasonably possible, should be the removal of that portion of the duodenum in which the ulcer is situated, together with the ulcer.

Working, as we do, in very close and intimate relation to the members of the Gastroenterological Department of the clinic, it must be realized that practically all patients with duodenal ulcer coming to the Surgical Department for subtotal gastrectomy have ulcers of the chronic, recurring type, intractable to medical management and often asso-

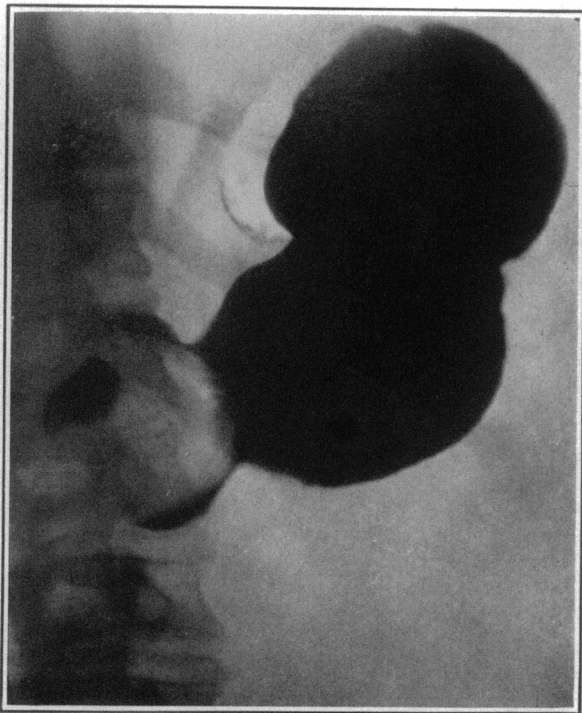


FIGURE 8. Roentgenogram of a Leiomyoma of the Stomach. This shows the typical roentgenographic defect seen with these lesions.

eaten — at least five a day — until at least a year or more has passed, by which time, in most of the cases, three meals of sufficient size can be taken at the regular intervals that have been established for all of us, and the interval feedings will not be necessary (Figs. 10 and 11).

Among the 89 cases of total gastrectomy there were 26 deaths, a mortality of 29.2 per cent, but of the patients operated on from January 1, 1942, through October 1, 1945, only 7 died, a mortality of 16.3 per cent.* The estimated chances of survival, based on 57 patients who survived operation and were followed, whether now living or dead,

*From follow-up data compiled by Dr. Frances H. Smith, Department of Gastroenterology, Lahey Clinic (to be published).

ciated with complications, such as recurring hemorrhages or pyloric obstruction. This means that in a high percentage these patients on whom we do subtotal gastrectomy have badly scarred duodenal ulcers that have eroded into the head of the pancreas and into the pancreaticoduodenalis artery, which runs on the back wall of the duodenum, and as a result of the induration and scarring, often have pyloric obstruction.

Over the years we have adhered quite strictly without much change to what we have published in

the hospital and in bed, where they have been relieved of emotional stress and strain, and by putting them on rigid dietary regimens and antispasmodics, with the result that in many cases the obstructions have been relieved, only to recur when the patients have resumed their work and activities under the stress and strain that frequently go with them, or when they have perhaps not adhered as rigidly to their dietary regimen as they should.

We have been disturbed at times by having to carry out surgical procedures on these patients late,

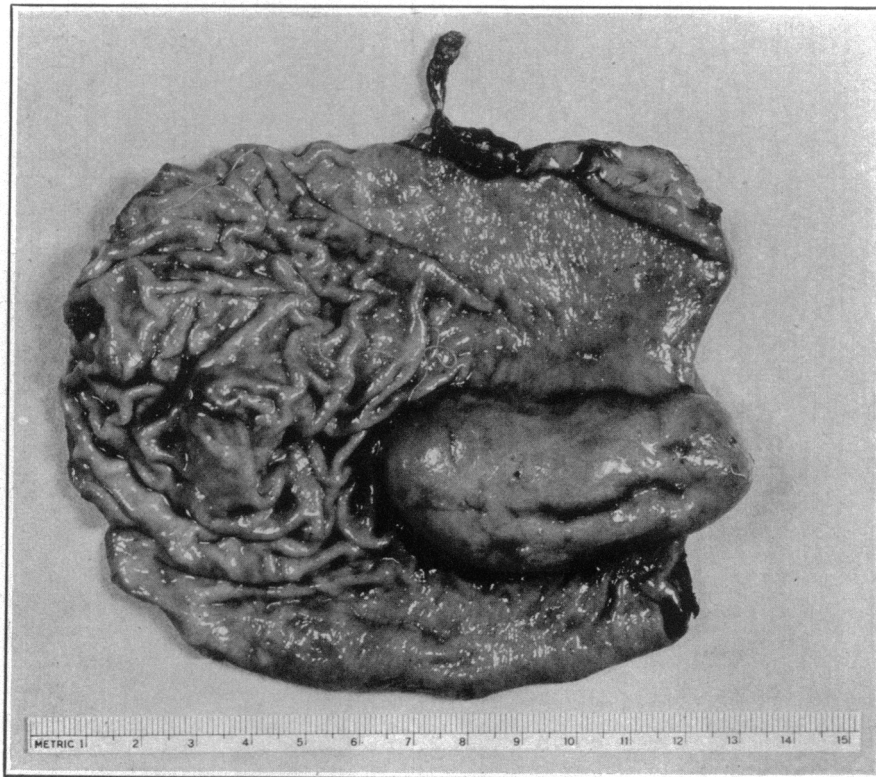

FIGURE 9. *Gross Specimen of the Leiomyosarcoma.*
Note the scars of previous ulceration and hemorrhages, as mentioned in the text. Microscopically this proved to be a leiomyosarcoma.

the past as our indications for surgery in duodenal ulcer. They are as follows: failure to relieve distress and pain by medical management; the occurrence of hemorrhage, particularly repeated hemorrhages, in spite of medical management; perforation, obviously an emergency indication for operation; and pyloric obstruction. This set of indications is so straightforward that they require little further discussion, except perhaps the matter of pyloric obstruction and hemorrhage.

I have repeatedly said that in the past we have often wasted time and money of patients with recurring pyloric obstruction by getting them into

at which time we have often thought that we should have done the operations sooner. We have sought, therefore, a plan whereby we could make earlier decisions in the patients with pyloric obstruction, particularly those related to duodenal ulcer, concerning when we could expect that the pylorus that we are able to open would remain open, when it would not remain open and when surgery was indicated.

Dr. S. Allen Wilkinson,⁴ in the Gastroenterological Department, has developed and published a plan that has been of great help to us in making this decision. It consists of putting an indwelling Levine tube in the patient's stomach through the nose,

feeding the patient who is known to have pyloric obstruction a 90-cc. noncurdling mixture through not decrease promptly within the three-day period from a high to a low figure, one can anticipate that

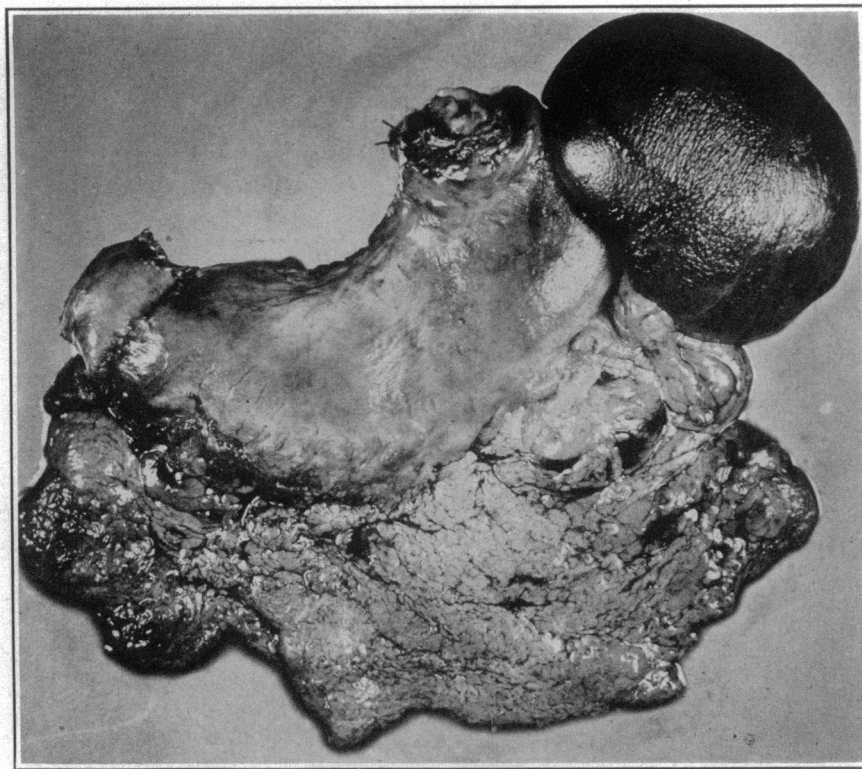


FIGURE 10. Surgical Specimen of a Total Gastrectomy for Carcinoma of the Linitis Plastica Type.

Note the entire removal of the stomach, the small cuff of duodenum with all of the omentum attached and the spleen.

the tube every hour for twenty-four hours and continuing this for three days. The tube is clamped for the first half-hour of each hour and is drained for the second half-hour, and the total amount of drainage obtained is recorded at the end of twenty-

the pylorus will not remain open and surgery will be necessary.

It is to be noted also in these patients who have pyloric obstruction that there is a time relation to the probability whether the pylorus will remain

TABLE 4. Results of Tube Drainage in Nonoperated Cases of Duodenal Obstruction.

CASE No.	DURATION OF OBSTRUCTION	6-HR. RESIDUE %	TUBE DRAINAGE* oz./day	RECURRENCE
1	6 mo.	90	41-24-18	1 yr. (operation)
2	2 mo.	Large	34-33-7-2	None
3	?	25	22-27-35-1-0	None
4	3 wk.	90	50-42-24	1 yr. (operation refused)
5	3 mo.	Large	31-34-40	6 mo. (operation)
6	?	Trac	53-19-18-10	None
7	10 days	Trac	23-22-30-9	Hemorrhage (2 mo.); operation.
8	4 mo.	50	45-20-4	None
9	10 mo.	Trace	26-22-6	None
10	2 wk.	10	21-20-9-3	None
11	2 yr.	90	44-45-50-41	3 mo. (operation)
12	2 mo.	70	24-5-1	None
13	2 yr.	Not known	56-23-31-17-19	Operation refused
14	5 mo.	90	20-5-1	6 mo. (operation)
15	?	50	10-10-10-4	None

*The figures represent the amounts on consecutive days.

four hours. When, as shown in Table 4, which lists a few examples of such cases, the drainage does

open under medical management. Table 5 shows that in those patients who had pyloric obstruction

for less than three months, 39 per cent⁴ required ultimate surgery, whereas of those who had pyloric obstruction three months or more, an increased percentage (69 per cent) ultimately required operation. This has proved a valuable procedure in our hands in saving patients time in the hospital and permitting us to arrive at an early decision in patients with pyloric obstruction concerning when operation was necessary.

One should not leave the matter of bleeding without again calling attention to the fact that there are two types of bleeding associated with duodenal

concerning whether radical operation is advisable. It is our opinion, as stated above, that when such a hemorrhage occurs in spite of a good regimen of medical management, subtotal gastrectomy is indicated.

It is to be remembered, however, that there is another rare but extremely dangerous type of hemorrhage associated with duodenal ulcer — that

TABLE 5. *Results of Drainage in 100 Cases of Duodenal Obstruction.**

DURATION OF OBSTRUCTION	OBSTRUCTION RELIEVED %	OBSTRUCTION RECURRENT %
Less than 3 mo.	61	39
More than 3 mo.	31	69

*Of these patients, 56 were relieved by drainage and 44 were eventually operated on.

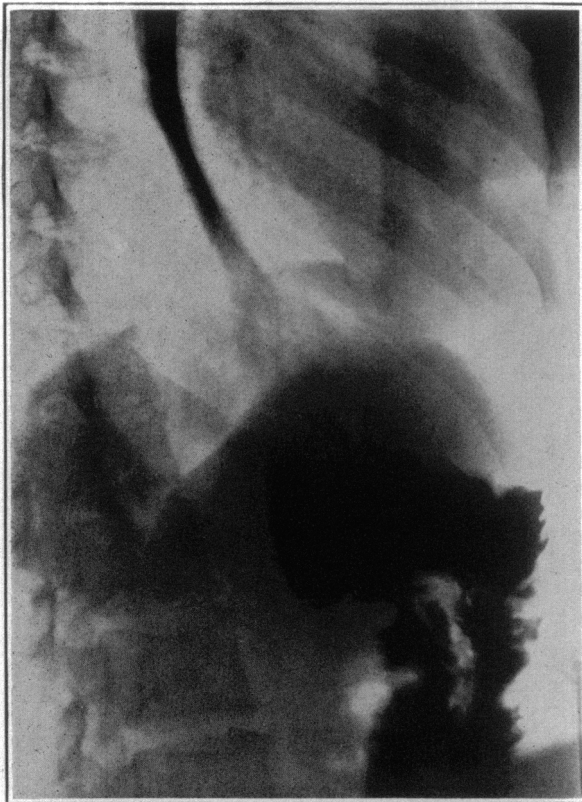

FIGURE 11. *Roentgenogram Taken Several Months after a Total Gastrectomy.*

Note the dilatation of the jejunum to serve as a substitute for the stomach. Note also the two loops of jejunum with an enterostomy at the lowest point of the jejunal loop. There is no dilatation of the esophagus.

ulcer. The more frequent one, that with which everyone is quite familiar, is the case with an occasional single hemorrhage from which, in spite of a considerable loss of blood, the patient promptly recovers. Many patients with peptic ulcer become callused to hemorrhages of this type and do not look on them with undue apprehension.

In this type of bleeding there is no surgical emergency and the decision can be made deliberately

is, the massive hemorrhage in which the bleeding persists and is of such magnitude and frequency as to result not infrequently in a fatality unless something desperate is done.

It is in these cases that an immediate decision must be made if these patients are to be saved. This decision must be made within forty-eight hours and often within twenty-four hours if, in spite of massive transfusions, one hopes to save these patients. It is to be remembered that hemorrhage is often more serious and fatal in patients over fifty years of age than in those under fifty years of age. This is not an easy decision to make, but in the presence of persisting and repeated hemorrhages from duodenal ulcers, where facilities and adequate experience are available, these patients should not be permitted to go on to such desperate states that ultimate surgery, when done, has little or no prospect of resulting in anything but a fatality.

Decision regarding what the approach to this serious problem is must remain in the judgment of the surgeon, based largely on what the patient will stand. In some of these cases we have saved the patient's life by subtotal gastrectomy, together with removal of the indurated ulcer, and control of the bleeding, even when the risk has been desperate. In others, so desperate has been the situation that we have opened the duodenum, transfixed the bleeding ulcer with silk and done a gastroenterostomy to overcome the obstruction that has resulted. The mortality in these cases will be high. In this selected group with recurring massive hemorrhages it is the only procedure, however heroic the measure may appear to be, that offers these patients a prospect of life.

As a result of this experience with subtotal gastrectomies for intractable duodenal ulcer, we can draw the following conclusions. The resection must be high (Figs. 12 and 13) in order to get out the largest number of acid-bearing glands. Our resections

have taken out as a minimum three fourths and in most cases four fifths of the stomach, and when it is reasonably possible, it is desirable to remove the ulcer and that portion of the duodenum in which it is situated. An antecolic anastomosis without enteroenterostomy has in our hands been the most satisfactory method of restoring the intestinal stream; it is not desirable to do an enteroenterostomy between the afferent and efferent loops of jejunum because of the fact that it sidetracks alka-

It is well to state to these patients that following subtotal gastrectomy they cannot eat anything they desire and cannot drink and smoke. If they wish to have the best prospect of nonrecurrence of their ulcers, in the form of gastrojejunal ulcers, they must remain on a postoperative diet that is almost as rigid as is the diet for the medical management of an ulcer that is to be treated without surgery. It must, I believe, be accepted that if a patient has once had an ulcer he is a prospect for

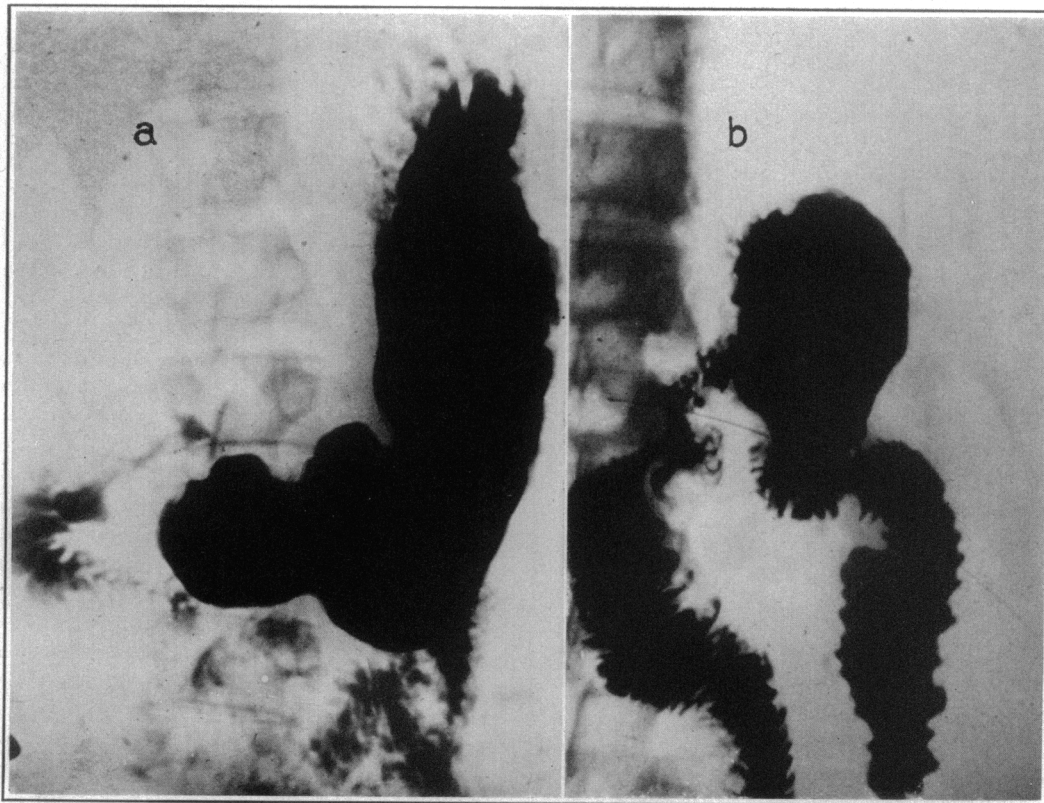


FIGURE 12. *Roentgenograms in a Case of Duodenal Ulcer.*

The one on the left was taken preoperatively. That on the right was taken after a high subtotal gastrectomy. Note the Hofmeister type of anastomosis, the small fraction of stomach remaining and the absence of any enteroenterostomy. These anastomoses are all of the antecolic variety.

line duodenal and jejunal contents beyond the stomach and prevents them from entering the stomach, as they do when no enteroenterostomy is done, thus helping to lower gastric acidity. When, as a result of subtotal gastrectomy, anacidity or acid values of 10 or below can be produced, there will be few if any gastrojejunal ulcers, and the end results will be good. It is not necessary in our experience after subtotal gastrectomy to do jejunostomies or to introduce indwelling Levine tubes into the stomach, since these patients can be fed almost immediately after operation and, if adequate stomas are left, drain quite promptly and are not, in the majority of cases, bothered by postoperative vomiting.

another ulcer in spite of the high subtotal gastrectomy unless he takes every precaution in the way of change in his eating and living habits to prevent its recurrence.

JEJUNAL ULCER

Jejunal ulcer, sometimes called gastrojejunal ulcer, stoma ulcer or marginal ulcer, probably occurs in a much higher percentage of patients on whom gastroenterostomies for duodenal ulcer have been done than has been assumed to be true in the years gone by. What the exact incidence is, we cannot be absolutely sure, but it can safely be said to be over 15 per cent. In addition, as shown in our figures concerning the time gastrojejunal ulcer has

occurred after gastrectomy, it is not safe to assume that if a patient who has had a gastroenterostomy for duodenal ulcer goes three or four years, he is safe from the occurrence of this lesion. In patients coming here for surgery who have had gastro-

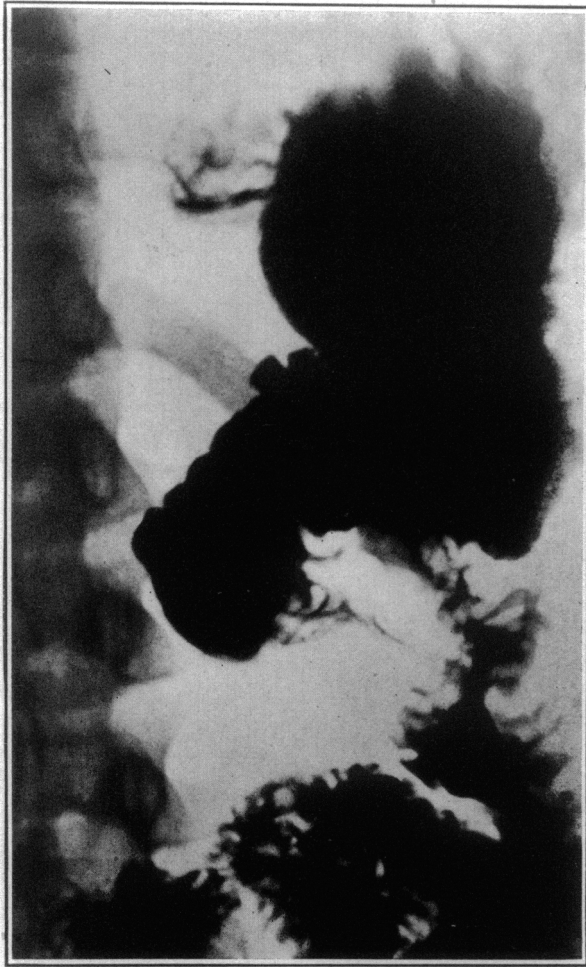

FIGURE 13. Roentgenogram of a Patient Who Developed a Gastrojejunal Ulcer after a Subtotal Gastrectomy.

The first operation, done elsewhere, was inadequate, and a second subtotal gastrectomy had to be done. Compare the extent of this resection with the resection in Figure 12 to demonstrate the radicalness of the procedure employed.

enterostomies for duodenal ulcers gastrojejunal ulcers have occurred as late as twenty-seven years after operation.

Jejunal ulcer is known to be an intractable type of ulcer, and used to be thought to be so intractable that surgery should be employed in every case. We have now dealt with a sufficient number of these cases so that we know that some of them can be handled medically and that, under such management, the ulcers will heal. In fact, it is our opinion that some jejunal ulcers occasionally heal spontaneously without accurate medical management. It is in all probability true that when a good gas-

troenterostomy has been done that later closes, the closure is the result of the cicatrix that follows the spontaneous healing of a gastrojejunal ulcer. We have several times seen such scars about the marginal stoma that brought about closure and must have been due to a healing of a previously existing gastrojejunal ulcer.

We believe that there is but one indication for immediate surgery in gastrojejunal ulcer, and that is when, as shown in Figure 14, it can be demon-

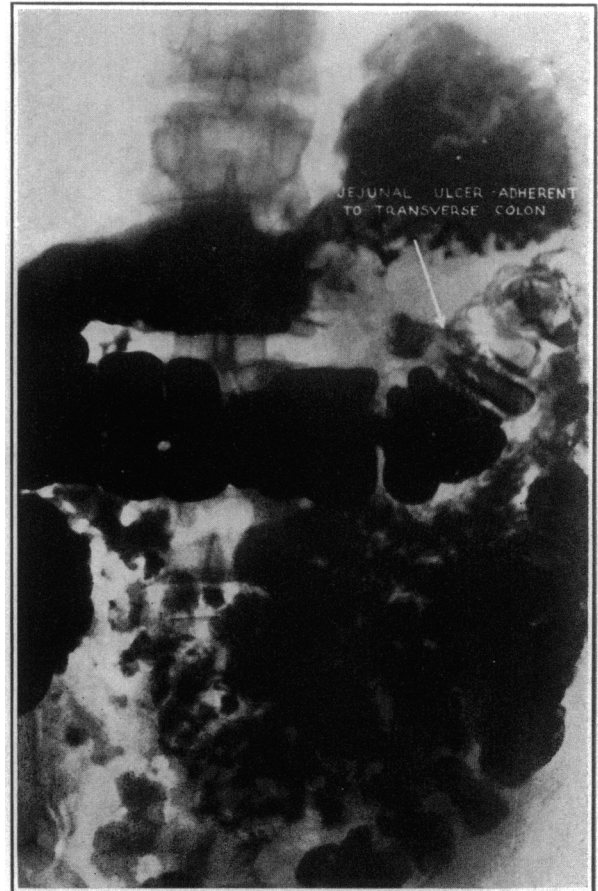

FIGURE 14. Roentgenogram Showing a Jejunal Ulcer Adherent to the Transverse Colon.

This ulcer was ready to produce a gastrojejunocolic fistula but, as proved by operation, it had not perforated.

strated that the jejunal ulcer is adherent to the transverse colon and in the process of perforating into the colon to form a gastrojejunocolic fistula.

In 87 consecutive patients who were operated on for gastrojejunal ulcer, the operation consisting of a high subtotal gastrectomy together with resection of that portion of the jejunum in which the stoma and the stomal ulcer existed, the mortality rate was but 2.3 per cent, demonstrating again that this lesion, although one of a complicated character, has even a lower mortality rate than that of duodenal

ulcer, again because of the fact that subtotal gastrectomy in duodenal ulcer, as already stated, is so often complicated by the fact that the ulcer is adherent to the head of the pancreas and to the common bile duct.

GASTROJEJUNOCOLIC FISTULA

Gastrojejunocolic fistula is by all means the most serious lesion with which one deals in gastric surgery. It is a perforation into the transverse colon of a jejunal ulcer that has become adherent to the transverse colon, producing a fistulous tract varying in size from one that will barely admit a straw to an aperture, as shown in Figure 15, the size of a ten-cent piece.

When large gastrojejunocolic fistulas occur, they result in a most undesirable physiologic state. They produce a condition that is comparable with pel-

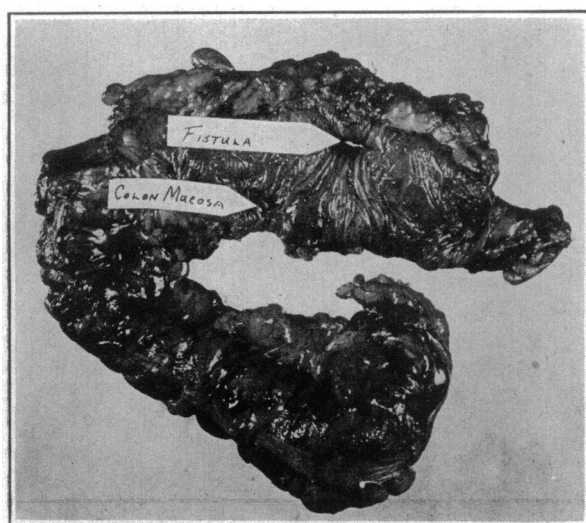


FIGURE 15. Specimen Removed at the Second-Stage Operation for Gastrojejunocolic Fistula.

The operation consists of partial colectomy, partial removal of the jejunum and subtotal gastrectomy. The gastrojejunocolic fistula is indicated by the arrow. Note its size and the amount of food that can be lost through it into the transverse colon.

lagra and a weight loss that is often startling. This is due to the fact that the constant escape of feces into the stomach discourages the desire for food and the constant escape of gastric contents into the transverse colon results in a pellagra-like state because it does not permit a good fraction of the food ingested to pass through the small intestine, where it can be absorbed for proper nourishment.

We have been through the employment of all types of procedures in an endeavor to handle patients with gastrojejunocolic fistulas successfully, and it was not until I devised the plan of cutting off the ileum at the ileocecal valve, turning the distal end in, and anastomosing the proximal end to the descending colon beyond the gastroenterostomy and

the fistula, with later subtotal gastrectomy and removal of the involved colon and jejunum, that we began to manage these cases successfully (Fig. 16).

I devised this plan of procedure with the idea that I could so advance that portion of the fecal stream in the small intestine beyond the gastroenterostomy that less of the colonic contents would pass back into the stomach; that it would establish the fecal stream beyond the gastroenterostomy so that at

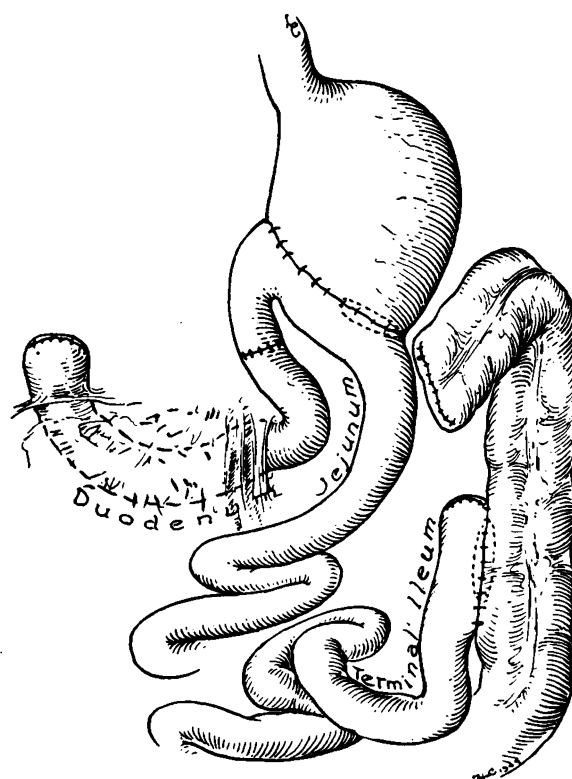


FIGURE 16.

This illustration shows the completed procedure for handling subtotal gastrojejunocolic fistula. Note the anastomosis of the ileum to the descending colon, which is the first stage of the operation. At the end of three months these patients return, at which time the ascending colon, transverse colon and the section of the jejunum in which the ulcer and fistula exist are removed in one piece, and a subtotal gastrectomy is performed. This illustration shows the status of the gastrointestinal tract when both stages of the operation are completed (reproduced from Marshall's by permission of the publisher).

the second stage of the operation when the subtotal gastrectomy together with the removal of the involved colon was undertaken, the anastomosis between the descending colon and the terminal ileum would already have been established and functioning. This operation has been successfully applied in 20 cases. In 2 of these the anastomosis of the ileum to the descending colon, a procedure that diverts the fecal stream from the ascending and transverse colon, has resulted in spontaneous closure of the fistulous tract after the first stage of the

operation and has resulted in there being no necessity for doing the radical second stage of the procedure to remove the fistula and the jejunal ulcer, together with the transverse colon.

It has been our experience in the remaining 18 cases in which the second stage of the operation has been done (Fig. 16), that if these patients are sent home for two to three months following the anastomosis of the ileum to the descending colon, thus advancing the fecal stream beyond the fistula, they will return at the end of this time in much improved general condition, with a gain in weight and with such improvement that the radical procedure of the second stage can be employed with a reasonable prospect of survival.

When one at first views this procedure, it appears to be so extensive as to unduly impress one with its magnitude. As we have done more and more of these operations, we have become aware that, with the fecal stream already established beyond the fistulous tract and with the patient in improved condition, it is possible, with reasonable ease, to cut the transverse colon off between the two rows of clips put in by the von Petz sewing machine beyond the fistula, just proximal to the splenic flexure, to turn the two ends in safety and to mobilize and devascularize the ascending colon and transverse colon, at which time the exposure becomes so adequate and complete that the operation, which consists of removing four fifths of the stomach, the involved segment of the jejunum and the ascending and transverse colon with the fistula into the splenic flexure, can be done more easily than the operation of subtotal gastrectomy and the removal of the jejunum alone in jejunal ulcer.

This is an operative plan for this serious lesion that offers the following advantages: the prospect that in a small percentage of cases following the implantation of the ileum into the descending colon, the fistula will heal spontaneously and the second stage of the operation will be unnecessary; and the fact that the marginal ulcer, together with the fistulous tract into the colon and that portion of the stomach to be removed in the subtotal gastrectomy, can be removed in one block without spilling colonic contents and without the dangers of colon-bacillus contamination that go with any operative procedure

in which a fistula into the colon has to be opened and the fistulous tract into the colon closed.

This procedure in our hands has made it possible to deal with these patients with gastrojejunal fistula, who are so often emaciated and in extremely poor condition, more satisfactorily than with any other type of procedure that has been proposed.

In the last ten years, this operation has been performed in 22 cases, with 2 deaths, a mortality of 9 per cent.

* * *

I have purposely avoided any detailed discussion of technical surgical procedures in this oration before this general audience.

The mortality rates in the four types of peptic ulcer — gastric, duodenal, jejunal and gastrojejunal fistulas — are given, as well as those of radical operations and of palliative operations for malignant lesions of the stomach.

The type of lesions in which total gastrectomy has been applied in 89 cases and the total mortality in this group, together with the change between the mortality rate in the first 46 cases and that in the last 43 cases, are included.

Some of the measures by which the now unsatisfactory end results of surgery for gastric cancer can be improved are stated.

The mortality rate with transthoracic resection of the lower end of the esophagus and cardiac end of the stomach is reported again in two groups to indicate the improvement, as in total gastrectomy, that has come with added experience and improved selection.

Hiatus hernia, peptic ulcer of the esophagus and leiomyoma of the stomach are discussed, as are gastric ulcer, duodenal ulcer, jejunal ulcer and gastrojejunal fistula, and experiences and mortality rates in handling this group of cases are given.
605 Commonwealth Avenue

REFERENCES

1. Chamberlain, D. T. Peptic ulcer of esophagus. *Lahey Clin. Bull.* 2: 59-63, 1940.
2. Marshall, S. F. Technic for subtotal resection of stomach for carcinoma. *Surg. Clin. North America* 25:679-690, 1945.
3. Lahey, F. H., and Colcock, B. P. Diagnosis and surgical management of leiomyomata and leiomyosarcomata of stomach. *Ann. Surg.* 112:671-686, 1940.
4. Wilkinson, S. A. Duodenal drainage: its place in modern medical practice. *Lahey Clin. Bull.* 1:26-30, 1940.
5. Marshall, S. F. Plan for surgical management of gastrojejunal fistula. *Ann. Surg.* 121:620-638, 1945.